

Coronary Stenting with M-Guard: Feasibility and Safety Porcine Trial

*Edo Kaluski, MD, §Adam Groothuis, MS, MBA, *Marc Klapholz, MD, §Philip Seifart, MS, HTL, ACSP, †Elazar Edelman, MD

ABSTRACT: M-Guard is an ultra-thin polymer mesh sleeve attached to the external stent surface. It is designed to minimize distal embolization during coronary, renal, carotid and vein graft stenting. The polymer net could also serve as a platform for more uniform drug delivery. **Aim.** To evaluate coronary M-Guard stent deliverability and safety (stent thrombosis and restenosis) in comparison to bare-metal stents (BMS) in a porcine model of percutaneous coronary interventions (PCIs). **Methods.** Under general anesthesia using percutaneous technique, 6 swine received a total of 18 coronary stents: 5 BMS and 13 M-Guard-BMS. Quantitative coronary angiography (QCA) was obtained immediately prior to and post-PCI, and at 30 days post-stenting. At 30 days, all animals were sacrificed and hearts were sent to a core lab for coronary histology and histomorphometry. Primary endpoints were 30-day QCA percent diameter stenosis, late luminal loss and minimal luminal diameter (MLD). Secondary endpoints were procedural success, 30-day mortality and stent thrombosis. Exploratory endpoints were histology and histomorphometric analysis performed at 30 days on M-Guard stented segments. **Results.** All stents were delivered successfully. There were no procedural complications or porcine morbidity or mortality at 30 days. The M-Guard and BMS displayed similar results of MLD, late luminal loss and percent diameter stenosis at 1 month. **Conclusion.** When compared to BMS, PCI with M-Guard-BMS is feasible, safe and yields similar inflammatory and restenotic response.

J INVASIVE CARDIOL 2007;19:326–330

Coronary and peripheral interventions can result in distal embolization. Although guidelines mandate the use of embolic protection devices (EPDs) in PCI of vein grafts¹ and carotid arteries,^{2,3} these devices are at most 50% effective⁴ and suffer from considerable shortcomings.⁵ Approximately 40%⁶–66%⁷ of patients undergoing carotid stenting with EPDs develop new MRI diffusion-weighted imaging defects. In certain emboli-prone vascular beds and settings (myocardial infarction), clinical trials employing EPDs could not demonstrate benefit.

From the *Department of Cardiology, University Medical Center, University of Medicine and Dentistry, Newark, New Jersey; the †Biomedical Engineering Center, Experimental Cardiovascular Interventional Laboratory, Boston, Massachusetts; and (Professor of Medicine) †Brigham and Women's Hospital and Harvard Medical School, and Massachusetts Institute of Technology, Boston Massachusetts.

Disclosure: Dr. Kaluski is a co-founder of Inspire-MD. He is a current stockholder in the company. This study was funded by Inspire-MD; The study was outsourced and conducted by an independent laboratory, which was responsible for study design, execution, data collection, interpretation and reporting.

Manuscript submitted March 16, 2007, provisional acceptance given May 7, 2007, manuscript accepted June 7, 2007.

Address for correspondence: Edo Kaluski MD, FACC, FESC, Director of Invasive Cardiology and Cardiac Catheterization Laboratories, University Hospital, University of Medicine and Dentistry of New Jersey, 185 South Orange Avenue, MSB I-538, Newark, NJ 07101. E-mail: kalusked@umdnj.edu




Figure 1. M-Guard prototype.

M-Guard (*Inspire-MD, Tel-Aviv, Israel*) is an ultra-thin, flexible polyethylene terephthalate (PET or Dacron) mesh sleeve fabricated by circular knitting. The M-Guard is anchored to the external surface of the stent (Figure 1). This biocompatible microfiber net (string diameter 10–22 microns) has minimal effects (< 0.1 mm) on the stent's crossing profile or deliverability. During stent deployment, the net is able to stretch, creating custom-designed pores of 200 microns in diameter (pores created by stent struts are 10- to 40-fold larger in diameter, translating into a 100- to 1,600-fold larger cross-sectional area). Hence, M-Guard has the theoretical potential to serve as a "built-in" and permanent EPD.

M-Guard can also be used as a potential platform for more uniform drug delivery, especially for drugs with reduced diffusion capacity. This potential application of the M-Guard is appealing in view of the delayed healing and imperfect endothelialization observed with current commercially available stent struts and platforms of drug-eluting stents (DES).¹⁰ Since the M-Guard mandates *in vivo* studies (due to anticipated use in humans), and pigs are an established and recommended model for coronary studies by regulatory agencies, Inspire-MD elected to delegate the design and execution of porcine studies to an independent animal cardiovascular laboratory (*Experimental Cardiovascular Interventional Laboratory, Boston, Massachusetts*).

The objective of this study was to assess the safety of M-Guard BMS in comparison to conventional BMS with regard to:

1. Deliverability (using conventional coronary guiding catheters and wires);
2. Incidence of stent thrombosis, porcine morbidity and mortality;
3. Extent of restenosis at 30 days post-deployment;
4. Assessment of the inflammatory response and severity of intimal hyperplasia by 30-day histology and histomorphometric measurements.

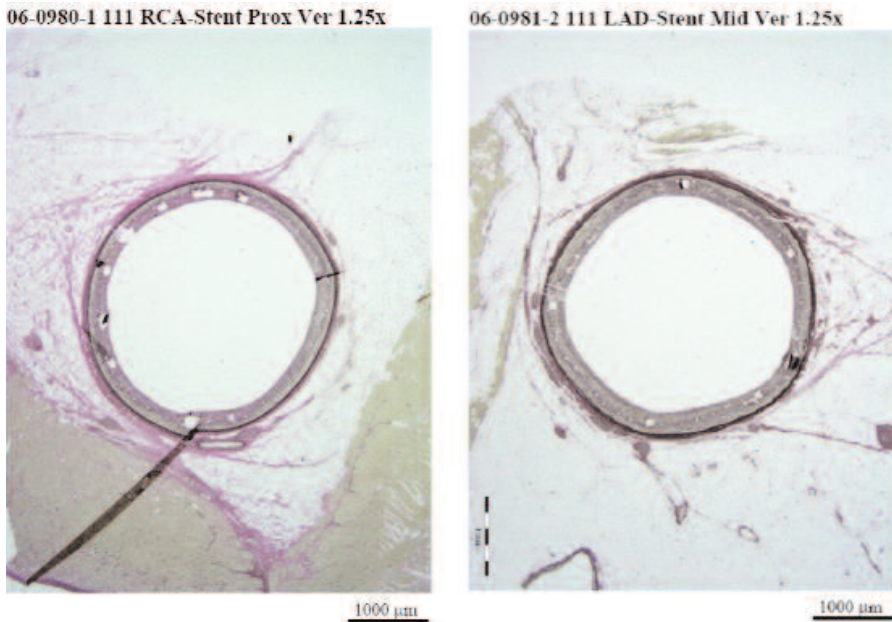


Figure 2. Macroscopic appearance 30 days post-M-Guard stenting of the right coronary and left anterior descending arteries.

Methods

Animals. This study used 6 castrated Yorkshire male swine (ages 4–10 months, weighing 30–60 kg). Housing, food and water were provided according to the *Guide for the Care and Use of Laboratory Animals*.

Device randomization. Each animal received 3 stents. Each of the major porcine coronary vessels was individually randomized to receive either a ClearFlex (*ClearStream Technologies, Ennis-corthy, Ireland*) BMS ($n = 5$), or a ClearFlex BMS with M-Guard ($n = 13$). All stents were 3 mm in diameter and 18 mm in length.

Procedure. *Premedication:* ≥ 12 hours prior to stenting, the animals were given 325 mg aspirin and 75 mg clopidogrel, which were continued daily for the duration of the study. Preoperative nifedipine (10 mg SL) and cephazolin (1 g intravenously [IV]) were also administered. Telazol 4.4 mg/kg intramuscular (IM), xylazine 2.2 mg/kg IM, atropine 0.05 mg/kg IM were administered as preanesthetic for induction of light anesthesia. Upon induction of light anesthesia, each animal was intubated. *Anesthesia:* isoflurane (1–5% to effect by inhalation) in oxygen was administered for the duration of the procedure. The level of anesthesia was monitored continuously by electrocardiography (ECG) and the animal's response to stimuli. *Intervention:* A femoral cutdown was performed and a 7 Fr arterial sheath was introduced into the femoral artery. Under fluoroscopic guidance, the 7 Fr guiding catheter was advanced through the sheath to the ostium of the coronary arteries. Heparin 200 u/kg IV bolus was administered. After nitroglycerin (200 μ g IV) was given, standard angiographic images were obtained (for assessing flow and quantitative coronary angiography [QCA]) and stent deployment sites were selected. A coronary guidewire

(0.014 inch) was advanced into the appropriate vessel. Stents (3 mm diameter, 18 mm length) were introduced into the coronary arteries through the guiding catheter and over the coronary guidewire and deployed in all 3 coronary arteries (left anterior descending, left circumflex and right coronary arteries) using “inflation pressures” sufficient to obtain a balloon-to-artery ratio of 1.1:1–1.2:1. Post-stenting standard angiographic views were obtained for flow assessment and QCA.

Follow up. Animals were observed for 1 month, and any unusual behavior or morbidity was charted. 4 weeks post-stenting, the animals were re-anesthetized, and coronary angiography was executed (using percutaneous femoral artery access). Heparin (20 U/kg, IV) and nitroglycerin (200 μ g intracoronary) were administered prior to standard-view angiograms.

After concluding the 30-day angiography, the animals were euthanized. The hearts were removed and perfusion-fixed at ~ 100 mmHg with lactated Ringer's solution until cleared of blood, followed by 10% neutral buffered formalin. The fixed hearts were placed in a fluid-filled container of fixative solution to preserve vessel integrity prior to histopathological evaluation.

Quantitative coronary angiography. QCA was performed by a reader blinded to the treatment assignments using TCS Symphony by Medcon (*Parsippany, New Jersey*), and employing standard methods described elsewhere.¹⁴

Histology. Studies were executed by an independent histologist (PS) who sampled the proximal, middle and distal portions of each stented segment. A vessel injury score was calculated using the method described by Schwartz et al.¹⁵ Qualitative assessment was done for inflammation, endothelialization, fibrin score and granuloma formation. These values were determined and averaged for the 3 segments. Histomorphometric measurements of intimal hyperplasia were measured and averaged alike.

Endpoints. The primary endpoint was 30-day QCA-derived percent diameter stenosis. The co-primary endpoint was 30-day late luminal loss and minimal lumen diameter by QCA. *Secondary endpoints* were procedural success, 30-day mortality and stent thrombosis. *Exploratory endpoints* were histology and histomorphometric studies of M-Guard stented segments assessing endothelialization, severity of inflammatory reaction and injury and extent of neointimal proliferation.

Statistical analysis. Data are expressed as mean \pm SD. Statistical analysis of the histologic and angiographic data comparing the two groups employed a non-paired t-test. Values of $p < 0.05$ are considered statistically significant.

Table 1. Primary endpoint.

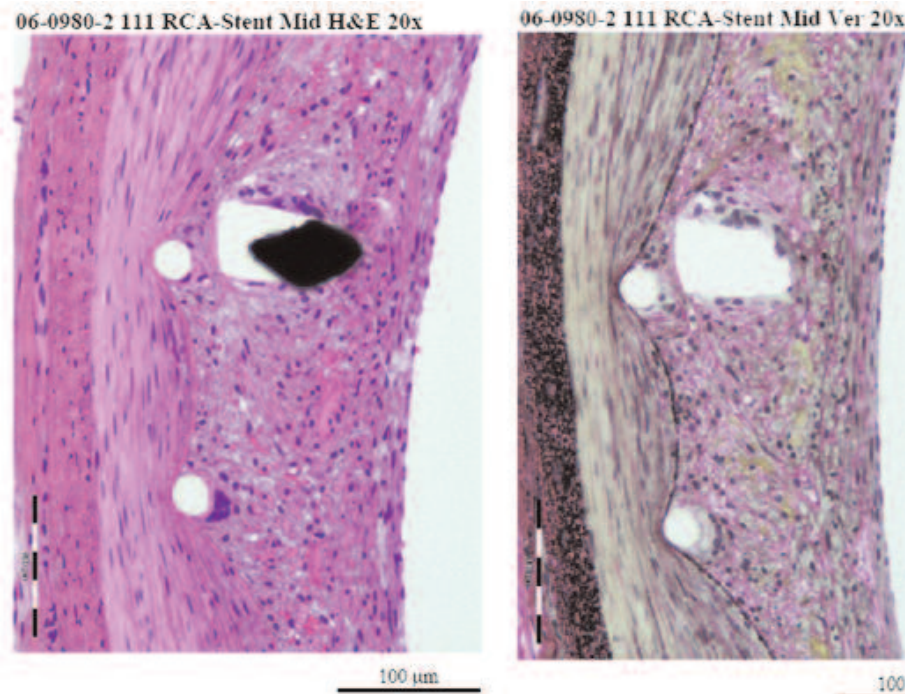
Parameter	M-Guard-BMS [§]	BMS [§]	p-Value
30-day % diameter stenosis*	47 ± 19%	46 ± 31	0.98
30-day late loss* (mm)	1.33 ± 0.53	1.30 ± 0.89	0.92
30-day minimal luminal diameter* (mm)	1.55 ± 0.58	1.50 ± 0.87	0.89
Reference vessel diameter* (mm)	2.77 ± 0.19	2.62 ± 0.09	0.11
Post-stent minimal diameter* (mm)	2.88 ± 0.16	2.80 ± 0.02	0.27
Balloon-to-artery ratio*	1.08 ± 0.04	1.09 ± 0.03	0.78

*Mean ± standard deviation
[§]BMS = bare-metal stent

Table 2. Histology.

Measurement	Mean ± SD	SEM
Inflammation score (0–3)	0.8 ± 0.3	-
Granuloma (number per cross-section surrounding struts)	0 ± 0	-
Schwartz injury score	0.1 ± 0.1	-
Endothelialization score (scale 0–4)	4 ± 0	-
Fibrin score (scale 0–3)	0.8 ± 0.3	-
3 segment average of neointima thickness (mm)	0.18 ± 0.06	0.03
Average % occlusion (%)	22.80 ± 7.49	3.74
In stent restenosis (%)	23.30 ± 7.71	3.85
Average intima (mm ²)	1.49 ± 0.54	0.27
Average media (mm ²)	1.24 ± 0.33	0.17
Average lumen (mm ²)	4.93 ± 8.6	0.43
Internal elastic lumen area (mm ²)	6.41 ± 0.85	0.42
External elastic lumen area (mm ²)	7.65 ± 0.55	0.22

SEM = standard error of mean

**Figure 3.** Histology 30 days post-M-Guard stenting of the right coronary artery.

Results

Vessel characteristics (Table 1). Mean vessel diameter before (2.77 ± 0.19 mm vs. 2.62 ± 0.09 mm; $p = 0.11$) and after stenting (2.88 ± 0.16 mm vs. 2.80 ± 0.02 mm; $p = 0.276$) were similar in the two treatment arms, as was the balloon-to-artery ratio ($1.08 \pm .04$ vs. $1.09 \pm .03$; $p = 0.78$). All vessels had normal epicardial flow (TIMI 3) at baseline, post-PCI and at 30 days.

Primary and coprimary endpoints. There was no significant difference between the M-Guard and the BMS with regard to late loss ($1.33 \pm .53$ mm vs. 1.30 ± 0.89 mm; $p = 0.92$), percent diameter stenosis (47 ± 19 % vs 46 ± 31 %; $p = 0.98$), and minimal luminal diameter ($1.55 \pm .58$ mm vs. 1.50 ± 0.87 mm; $p = 0.89$).

Secondary endpoints. All stents were delivered successfully, resulting in 100% procedural success. There were no procedural complications or incidents of porcine morbidity or mortality at 30 days.

Exploratory endpoints (Table 2). Histology and histomorphometric data from the M-Guard stented segments suggest that M-Guard yielded acceptable inflammatory response (0.8 ± 0.3 on a scale of 0–3), with the absence of medial necrosis, mineralization, neovascularization or granuloma response. Low Schwartz injury scores (0.1 ± 0.1), acceptable fibrin score (0.8 ± 0.3 on a scale of 0–3+) and exceptionally good endothelialization (4 ± 0) were noticed. The extent of intimal hyperplasia was very acceptable and similar to historic BMS (average neointimal thickness 0.18 ± 0.06). Typical histologic segments of M-Guard stenting are presented in Figures 3 and 4.

Discussion

This study provides initial safety data on M-Guard stenting. It appears that the M-Guard can be safely delivered with conventional PCI equipment. Excessive thrombotic or animal morbidity and mortality were not observed with the device. Relative to

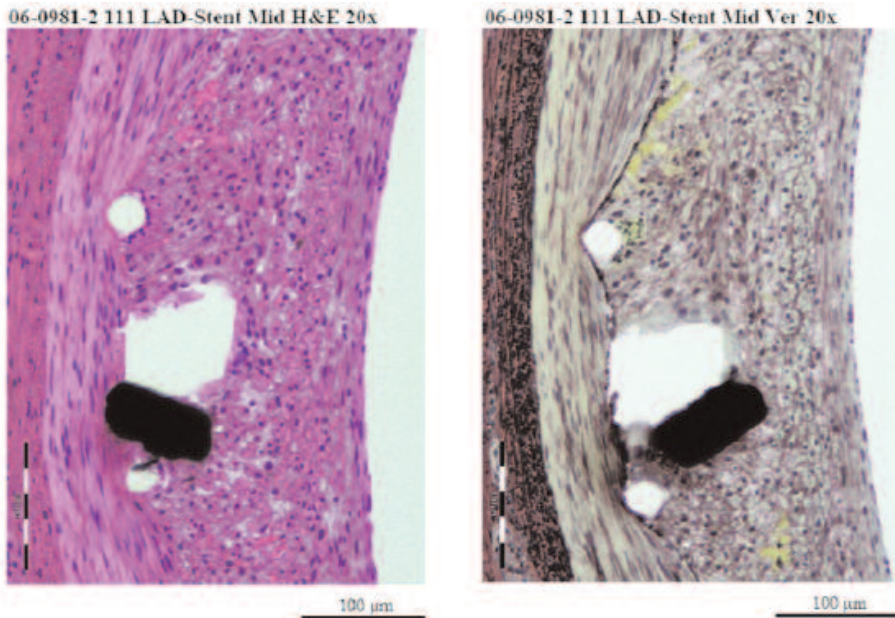


Figure 4. Histology 30 days post-M-Guard stenting of the left anterior descending artery.

BMS, the extent of inflammation, endothelialization, injury and intimal hyperplasia were very acceptable.

Although normal male porcine arteries may underscore the complexity of the pathologic process of the aging human coronary artery, the porcine model is preferred for coronary therapeutic testing,¹⁶ coronary interventions and DES.^{17,18} A few reports suggest that polymer,¹⁹ or specifically polyurethane strut coating, results in enhanced hemocompatibility (reduced platelet and white blood cell deposit)²⁰ when compared to other methods of strut surface modification.

Others reported²¹ that covering the entire stent with a polymer braid (net) results in enhanced inflammatory reaction, yielding excessive neointimal hyperplasia. In the rabbit carotid model, employing a microporous (pore diameter of 100 microns; interpore distance of 200 microns) polyurethane-covered stent, it was noted that the neointimal hyperplasia was somewhat more intense than with the noncovered BMS, but was less intense than the conventional covered stents.²²

Previous attempts to cover stents with polyurethane or fibrin film soaked in heparin in a swine model resulted in a 10% stent thrombosis rate and early porcine fatality in the former, and a 6% rate in the latter.²³ Stents struts covered with Poly-bis-trifluoroethoxy phosphazene resulted in a similar inflammatory reaction and neointimal hyperplasia at 6 weeks and 6 months when compared to BMS.²⁴ It is still not clear whether polymer coating for drug delivery or future biodegradable stents enhances biocompatibility, thus this issue remains a subject of intense investigation.²⁵ It is also debatable whether inflammatory reaction observed with polymers is related to the polymer or to contamination.

Although M-Guard BMS appears safe in this preliminary study, the efficacy of this innovation in preventing procedure-

related distal embolization or drug delivery remains to be proven. Future studies should assess the effect of this device on the incidence and severity of distal embolization during interventions in emboli-prone vascular beds.

Study Limitations

This study was not powered to detect even clinically meaningful excessive stent thrombosis or restenosis events.

Although the study was requested by the sponsor (Inspire-MD), the sponsor transferred the responsibility for study design, execution, data collection, data analysis and reporting to an independent laboratory and investigator (AG) and pathologist (PS) to minimize potential bias and conflict of interest.

Conclusion

This pilot (feasibility) study suggests that M-Guard can be delivered successfully employing conventional PCI wires and guiding catheters. Major adverse events and the extent of inflammatory process and intimal hyperplasia were similar to BMS. The use of M-Guard was not associated with any excessive medical complications or adverse events.

Addendum. Inspire-MD engaged in polymer purification processes in an attempt to further eliminate any potential inflammatory and foreign body reactions. A second, larger porcine trial with 1-, 3- and 6-month angiographic and histomorphometric assessment (*Groothuis A, et al. The Experimental Cardiovascular Laboratory, Boston, INSP-SO2-06*) demonstrated histomorphometry and QCA results of MGuard compared to BMS. Percent diameter stenosis by QCA at 3 and 6 months was 19.5% and 24.4%, respectively. The report concluded that: "...the polymer coating does not elicit adverse responses at time points extending out to 6 months". The encouraging porcine coronary data have prompted the launch of porcine carotid studies (using self-expanding stents with M-Guard), porcine renal artery studies, human saphenous vein graft and native coronary studies in Europe.

Acknowledgement. The authors wish to acknowledge the scientific and administrative contributions of Asher Holzer, Ofir Paz and Eli Bar from Inspire-MD, Ltd.

References

1. Silber S, Albertsson P, Aviles FF, et al for the Task Force for Percutaneous Coronary Interventions of the European Society of Cardiology. Guidelines for percutaneous coronary interventions. The Task Force for Percutaneous Coronary Interventions of the European Society of Cardiology. *Eur Heart J* 2005;26:804-847.

2. American College of Cardiology Foundation; American Society of Interventional & Therapeutic Neuroradiology; Society for Cardiovascular Angiography and Interventions; Society for Vascular Medicine and Biology; Society of Interventional Radiology; Bates ER, Babb JD, Casey DE Jr, et al. ACCF/SCAI/SVMB/SIR/ASITN 2007 clinical expert consensus document on carotid stenting: A report of the American College of Cardiology Foundation Task Force on Clinical Expert Consensus Documents (ACCF/SCAI/SVMB/SIR/ASITN Clinical Expert Consensus Document Committee on Carotid Stenting). *J Am Coll Cardiol* 2007;49:126–170.
3. Liistro F, Di Mario C. Carotid artery stenting. *Heart* 2003;89:944–948.
4. Baim DS, Wahr D, George B, et al. Saphenous vein graft Angioplasty Free of Emboli Randomized (SAFER) Trial Investigators. Randomized trial of a distal embolic protection device during percutaneous intervention of saphenous vein aorto-coronary bypass grafts. *Circulation* 2002;105:1285–1190.
5. Gorog DA, Foale RA, Malik I. Distal myocardial protection during percutaneous coronary intervention: When and where? *J Am Coll Cardiol* 2005;46:1434–1445.
6. Lacroix V, Hammer F, Astarci P, et al. Ischemic cerebral lesions after carotid surgery and carotid stenting. *Eur J Vasc Endovasc Surg* 2007;33:430–435.
7. Roh HG, Byun HS, Ryoo JW, et al. Prospective analysis of cerebral infarction after carotid endarterectomy and carotid artery stent placement by using diffusion-weighted imaging. *AJNR Am J Neuroradiol* 2005;26:376–384.
8. Stone GW, Webb J, Cox DA, et al for the Enhanced Myocardial Efficacy and Recovery by Aspiration of Liberated Debris (EMERALD) Investigators. Distal microcirculatory protection during percutaneous coronary intervention in acute ST-segment elevation myocardial infarction: A randomized controlled trial. *JAMA* 2005;293:1063–1072.
9. Limbruno U, De Caterina R. EMERALD, AIMI, and PROMISE: Is there still a potential for embolic protection in primary PCI? *Eur Heart J* 2006;27:1139–1145.
10. Grines CL, Bonow RO, Casey DE Jr, et al. for the American Heart Association; American College of Cardiology; Society for Cardiovascular Angiography and Interventions; American College of Surgeons; American Dental Association; American College of Physicians. Prevention of premature discontinuation of dual antiplatelet therapy in patients with coronary artery stents: A science advisory from the American Heart Association, American College of Cardiology, Society for Cardiovascular Angiography and Interventions, American College of Surgeons, and American Dental Association, with representation from the American College of Physicians. *J Am Coll Cardiol* 2007;49:734–739.
11. Division of Cardiovascular, Respiratory, and Neurology Devices, Interventional Cardiology Devices Branch. Guidance for the Submission of Research and Marketing Application for Interventional Cardiology Devices: PTCA Catheters, Atherectomy Catheters, Lasers, and Intravascular Stents; Food and Drug Administration, Center for Devices and Radiological Health, U.S. Dept of Health and Human Services; May 1995.
12. Schwartz RS, Edelman ER, Carter A, et al. Drug-eluting stents in preclinical studies: Recommended evaluation from a consensus group. *Circulation* 2002;106:1867–1873.
13. NRC (National Research Council). Guide for the Care and Use of Laboratory Animals. Washington, D.C.: National Academy Press, 1996.
14. Lansky AJ, Desai K, Leon MB. Quantitative coronary angiography in regression trials: A review of methodologic considerations, endpoint selection, and limitations. *Am J Cardiol* 2002;89(4A):4B–9B.
15. Schwartz RS, Huber KC, Murphy JG, et al. Restenosis and the proportional neointimal response to coronary artery injury: Results in a porcine model. *J Am Coll Cardiol* 1992;19:267–274.
16. Vollmar B, Bay W, Ozbek C, et al. Experimental intracoronary stenting: Comprehensive experience in a porcine model. *Lab Anim* 1998;32:191–199.
17. Schwartz RS, Edelman ER, Carter A, et al. Consensus Committee. Drug-eluting stents in preclinical studies: Recommended evaluation from a consensus group. *Circulation* 2002;106:1867–1873.
18. De Scheerder I, Wang K, Zhou XR, et al. Neointimal hyperplasia and late pathologic remodeling in a porcine coronary stent model. *J Invasive Cardiol* 1999;11:9–12.
19. Mrowietz C, Franke RP, Seyfert UT, et al. Hemocompatibility of polymer-coated stainless steel stents as compared to uncoated stents. *Clin Hemorheol Microcirc* 2005;32:89–103.
20. Tepe G, Schmehl J, Wendel HP, et al. Reduced thrombogenicity of nitinol stents — In vitro evaluation of different surface modifications and coatings. *Biomaterials* 2006;27:643–650.
21. Schurmann K, Vorwerk D, Uppenkamp R, et al. Iliac arteries: Plain and heparin-coated Dacron-covered stent-grafts compared with noncovered metal stents — An experimental study. *Radiology* 1997;203:55–63.
22. Nakayama Y, Nishi S, Ishibashi-Ueda H, et al. Development of microporous covered stents: Geometrical design of the luminal surface. *Int J Artif Organs* 2005;28:600–608.
23. Holmes DR, Camrud AR, Jorgenson MA, et al. Polymeric stenting in the porcine coronary artery model: Differential outcome of exogenous fibrin sleeves versus polyurethane-coated stents. *J Am Coll Cardiol* 1994;24:525–531.
24. Huang Y, Liu X, Wang L, Li S, et al. Long-term biocompatibility evaluation of a novel polymer-coated stent in a porcine coronary stent model. *Coron Artery Dis* 2003;14:401–408.
25. Bertrand OF, Sipehia R, Mongrain R, et al. Biocompatibility aspects of new stent technology. *J Am Coll Cardiol* 1998;32:562–571.